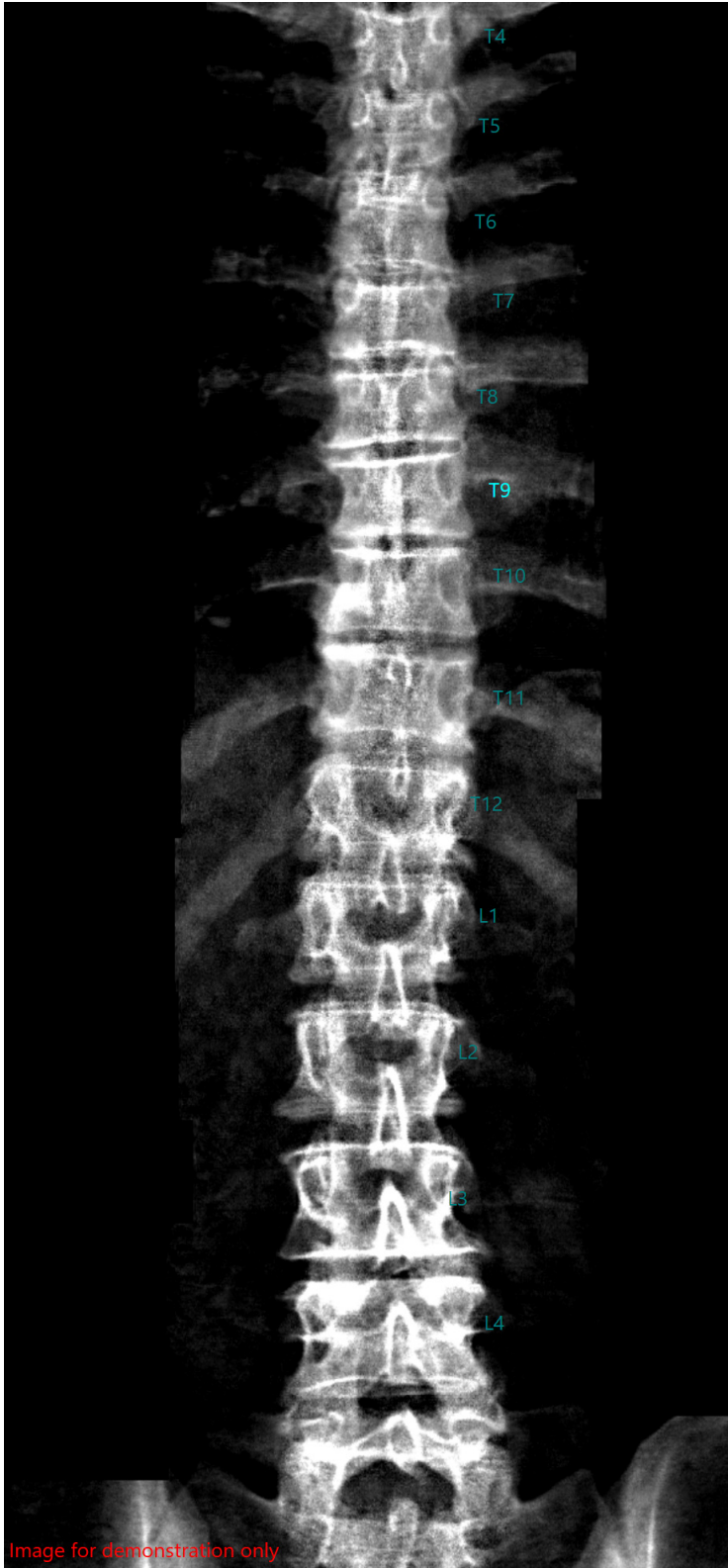





Patient:	Agawa, Alissa
Birth Date:	24-Mar-1967
Age:	35.5 years
Height / Weight:	170.2 cm 61.2 kg
Sex / Ethnicity:	Female Asian
Patient ID:	611303
Referring Physician:	Dr. Crusher
Measured:	02-Oct-2002 3:35:34 PM (7.00)
Analyzed:	08-Apr-2020 1:46:25 PM (18 [SP 1])

APVA Morphometry

Region	Deformity
T8	 Mild Biconcavity
T9	None
T10	None
T11	None
T12	 Mod. Wedge
L1	None
L2	None
L3	None
L4	None

COMMENTS: