



Compendium of TBS
Clinical Case Studies

bone structure matters

Compendium of TBS Clinical Case Studies

Medimaps Group thank all the authors for their contribution.

TBS iNsite™ is a software program to evaluate bone microarchitecture in clinical practice and enhance fracture risk prediction.

TBS is an independent risk of fracture and therefore an additional clinical risk factor. As such, it should be interpreted in accordance with appropriate guidelines and according to the good practice – as defined in the Position Development Statements of the International Society for Clinical Densitometry (ISCD).

This document contains clinical cases provided by physicians using TBS iNsite in their practice. As such, it reflects their own clinical experience and should not serve as medical instructions. Only the healthcare professionals can take medical decisions based on clinical judgment and on all available clinical information.

Compendium of TBS Clinical Case Studies first edition: March 2016

Reference: MM-BR-124-GE-EN-01

Table of Contents

TBS & Patient Management

<i>Case 1</i>	Dr Gerardo Aguilar <i>63-year old woman with osteopenic BMD–low TBS</i>	<i>04</i>
<i>Case 2</i>	Dr Gerardo Aguilar <i>67-year old woman with osteopenic BMD–low TBS</i>	<i>05</i>
<i>Case 3</i>	Dr Christine Simonelli <i>Interview & Clinical case</i> <i>62-year old woman with normal BMD–low TBS</i>	<i>07</i>
<i>Case 4</i>	Dr Luis Del Rio & Dr Silvana Di Gregorio <i>70-year old woman & 2 years follow-up results</i>	<i>10</i>

FRAX Adjusted for TBS

<i>Case 5</i>	Dr Neil Binkley <i>65-year old woman with osteopenic BMD–low TBS</i>	<i>12</i>
---------------	--	-----------

63-year Old Woman Osteopenic BMD–Low TBS



*By Dr Gerardo Aguilar, General Practitioner & Clinical Densitometrist
Clinica Bajío Clinba, Guanajuato, México.*

■ Patient Clinical Background

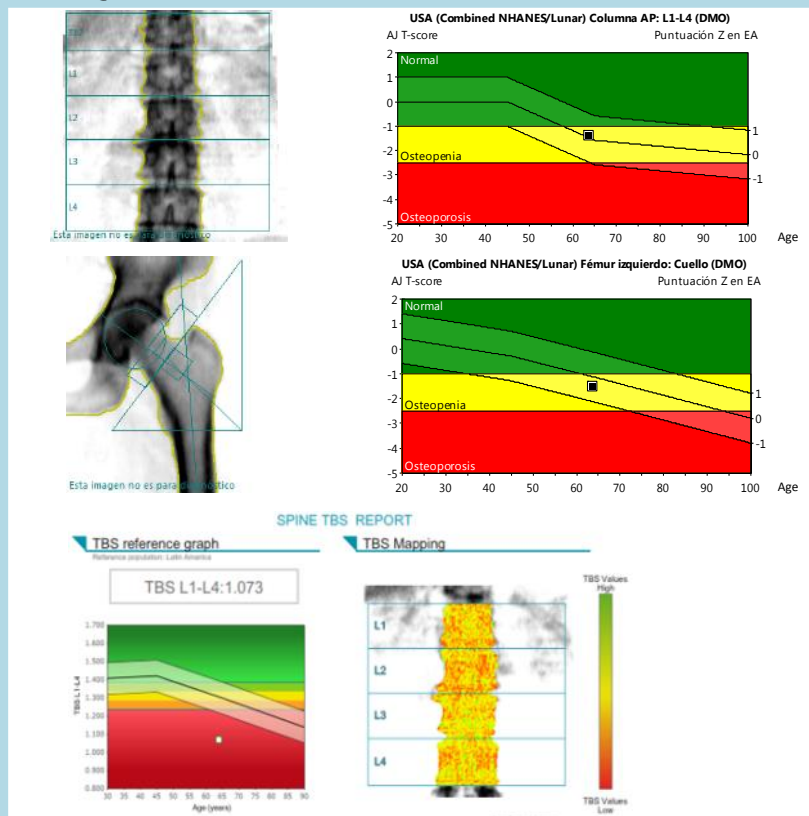
This is a 63-year old woman who was referred for bone density testing, with the following important medical backgrounds: mother with forearm history fracture, no previous fracture, regular calcium and vitamin D intake, hysterectomy at age 41 (no oophorectomy).

■ Bone Assessment & Analysis Images

Osteopenic Spine BMD
Spine T-Score (L1-L4): -1.4

Osteopenic Femur BMD
Femoral Neck BMD T-score: -1.5
Total Hip BMD T-score: -1.3

Low TBS value
Spine TBS (L1-L4): 1.073



■ Conclusion & Patient Management Decision:

FRAX® result: 4.7% for major osteoporotic fracture, 0.8% for hip fracture.

CAROC assessment: Low risk fracture.

However TBS score was reported as degraded (below 1.200).

FRAX® Adjusted for TBS: 7.5% for major osteoporotic fracture; 1.52% for hip fracture.

Based on clinical risk fracture of the patient our recommendation was to assure an adequate calcium intake as well as Vitamin D, and a training exercise for bone strength.

Referral physician decided to start anti-resorptive treatment (Risedronate 5mg daily).

67-year Old Woman Osteopenic BMD–Low TBS



By Dr Gerardo Aguilar, General Practitioner & Clinical Densitometrist
Clinica Bajío Clinba, Guanajuato, México (1/2)

❏ Patient Clinical Background & Clinical Assessment

This is a 67-year old woman who was referred to our clinic for bone density testing.

Important background records were: hysterectomy (without oophorectomy), omeprazole use sporadically, height loss and a metatarsal fracture 5 years ago.

No diabetic or other comorbidities.

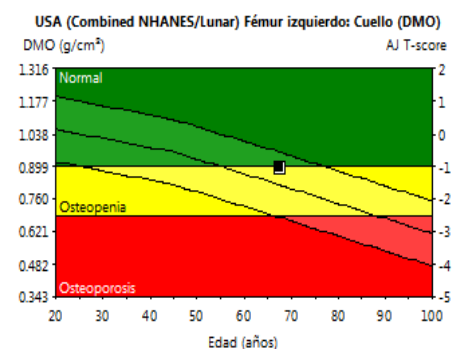
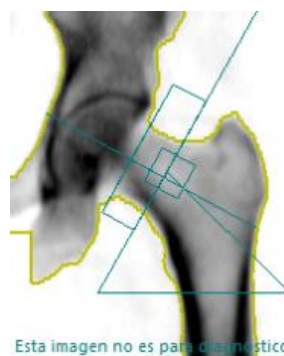
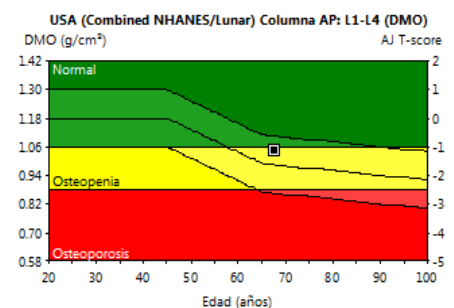
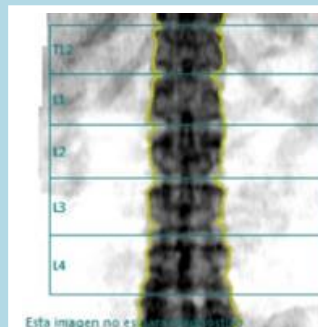
❏ Bone Assessment & Analysis Images

Osteopenic Spine BMD
Spine T-Score (L1-L4) : -1.1

Normal Femur BMD
Femoral Neck BMD T-score: -1.0
Total Hip BMD T-score: 0.1

Low TBS value

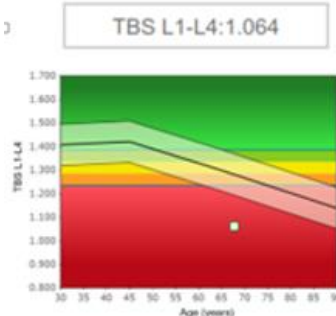
Spine TBS (L1-L4): 1.064



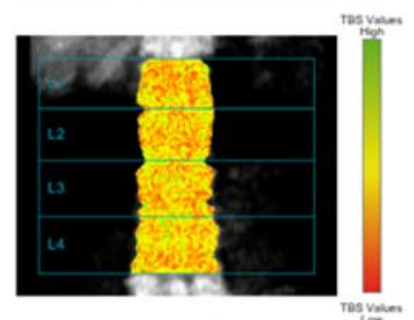
SPINE TBS REPORT

TBS reference graph

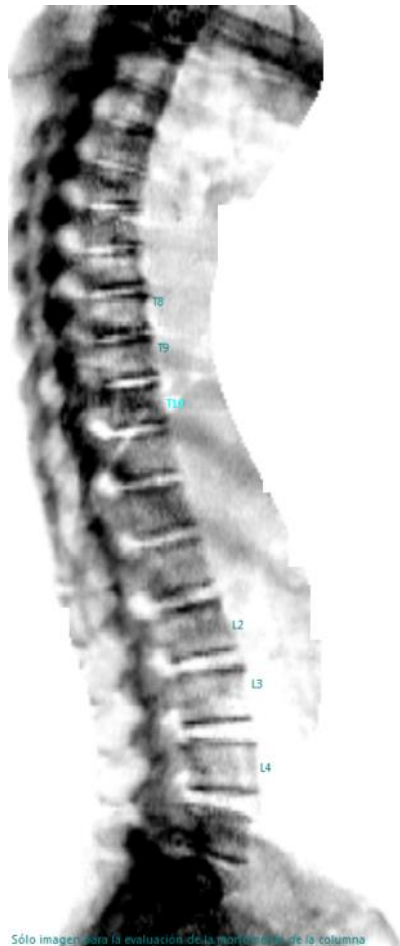Reference population: Latin America



TBS Mapping



Vertebral Fracture Assessment



Date of birth	10/09/1946
Age	67.6 y
Height / Weight	157.0 cm / 70.4 kg
Ethnicity	Hispanic

	Region	Alt. Med.		Coeficiente A/P	
		(cm)	Z-score	(%)	Z-score
	T8	1.49	-0.5	99	1.3
	T9	1.51	-0.8	106	2.1
	T10	1.57	-1.1	95	0.1
	L2	2.23	0.2	108	1.3
	L3	2.26	0.1	106	0.8
	L4	2.19	-0.3	100	-0.8

Conclusion & Patient Management Decision

According to patient age and previously reported metatarsian fracture, patient was originally classified in moderate risk for fracture; but due to the TBS result and the results of the VFA & history of height loss, the patient was considered to be at higher risk for fracture and pharmacological treatment was indicated.

Interview & Clinical case 62-year Old Woman Normal BMD–Low TBS



By Dr Christine Simonelli,
Board Certified in Internal Medicine and Clinical Densitometrist
HealthEast Osteoporosis Care, Greater Minneapolis, MN, USA (1/3)



Interview:

Medimaps Group: From your activity within HealthEast Clinics, the ISCD and Own the Bone, you have a great experience in Osteoporosis Management. Would you share with us your feedback on TBS and what it brings to clinicians for osteoporosis management?

Dr Simonelli: I am very happy you ask the question, because I have been using TBS for a year now and I think it is a great tool! In my practice TBS is very useful during the whole patient management process, helping in decision making for diagnosis, treatment and patients' follow-up care.

I analyze the TBS of all eligible patients. It enables me to complete the diagnosis by adding an estimation of bone microarchitecture to the tools we are already using the estimation of density (BMD) and estimation of future fracture (FRAX®) for our low bone density patients.

When the diagnosis of a patient's bone status is clear, TBS is reassuring. When you have cases where the decision to treat or not is equivocal, which we often do, TBS clearly brings added valuable information to identify patients at risk. It helps a lot in cases where the bone density measurement with DXA may not be telling the whole story, such as in patients with diabetes or those using glucocorticoids. The Trabecular Bone Score adds to the assessment of bone strength in these patients.

M.G.: This is very interesting. What about treatment and patient follow-up?

Dr Simonelli: TBS helps to identify patients with degraded bone structure who are therefore more likely to break a bone. Knowing the TBS of my patient helps me to decide to initiate treatment and then to select the most appropriate treatment. The effects on bone structure differ from one treatment to another (Ex: bisphosphonates vs. Denosumab), so knowing the TBS helps in my selection of drug therapy.

Compliance and adherence with the selected treatment is also critical and needs to be monitored closely. The TBS is useful in following the patient's progress over time, and it is a tool that allows me to verify the impact of the selected treatment on a patient's bone structure. It allows me to adapt treatment according to the evolution of my patient's TBS.

A TBS follow-up examination after 2 years of treatment helps me reevaluate my treatment choice. For example, it is an added tool in deciding on a drug holiday in selected patients if the TBS has increased, or to continue with my treatment if a positive effect is observed in a high risk patient. It can direct me to a change in therapy if no positive effect on bone structure is noted.

Dr Christine Simonelli – Interview (2/3)

M.G.: You have been working with TBS and presented several studies already. Would you like to tell us what you have been focusing on and what were your findings?

Dr Simonelli: We have been working on the American Caucasian-Women reference curve, and have in a second study compared the values of this curve to the ones of the existing European curve [this was part of the ASBMR 2013 scientific program].

From our database, we have analyzed TBS values to subcategorize patients and define TBS thresholds for patient management. Using this curve makes it very easy to interpret TBS in daily practice, since we now can compare our patients to the "normal" population.

M.G.: Was it easy for you to integrate TBS iN Sight® into your center, and is it easy to use?

Dr Simonelli: Yes it is a very easy-to-use software program, and most importantly, it is very easy to interpret and incorporate into a clinically useful DXA report. At HealthEast, the TBS analysis is done on every scan being done on a post-menopausal woman and reports are provided to the ordering physician and to the patient.

M.G.: Thank you, Christine. We understand that TBS is very useful for patient management. Would you say it is a useful innovation in the bone densitometry field?

Dr Simonelli: TBS compliments the existing equipment that we are currently using. Bone densitometry technology is continuing to advance, but DXA gives estimation of calculated volumetric bone density by giving us an areal measure. With TBS on our DXA equipment, we can now benefit from an estimation of the bone microarchitecture at the same time that we perform bone density testing with DXA. So yes, I would say it is a great innovation in the field of bone assessment.

M.G.: TBS "examination" just takes a few seconds, but is not reimbursed yet. Would you still recommend using it? Do you think it should be reimbursed in the near future?

Dr Simonelli: TBS gives us significant added-value information and it is time to start asking for reimbursement.

I don't believe our patients should pay any additional fee to benefit from advanced technologies for their examination. So reimbursement for TBS as an important tool giving us important information to use in the evaluation and management of the patient would indeed be appropriate.

M.G.: You may want to share some clinical cases you encountered that illustrate TBS added-value for the diagnosis, understanding and management of your patients' disease, or treatment selection and follow-up?

Dr Simonelli: Yes, sure

Check the selected clinical case of Christine next page.

M.G.: Of course, if there is any comment you would like to add, please feel free.

Dr Simonelli: Using the TBS software and showing TBS reports to my patients is an important tool to help our patients understand the need to accept a treatment. Compliance with osteoporosis therapy is a big problem and as a silent disease until a fracture occurs, we need clear evidence to help our patients understand the need for pharmaceutical therapy when they are feeling well. Demonstrating the TBS report is an important tool to help our patients understand this need by understanding their disease better.

I also believe that it is a priority for centers of excellence providing osteoporosis care to utilize the highest quality diagnostic tools to help care for our patients, including the trabecular bone score. That is why we are using highest standard and up-to-date technologies.

TBS has been a worthwhile investment for our medical center and osteoporosis service.

■ Patient Clinical Background

This is a 62-year old woman who was referred for bone density testing and evaluation because of multiple stress fractures of the metatarsals and fibula. The participant had a history of hysterectomy with bilateral oophorectomy and was on estrogen supplementation as her only prescription medication. She had just been started on calcium and vitamin D by her primary physician.

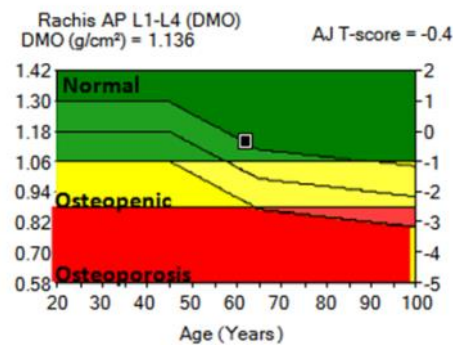
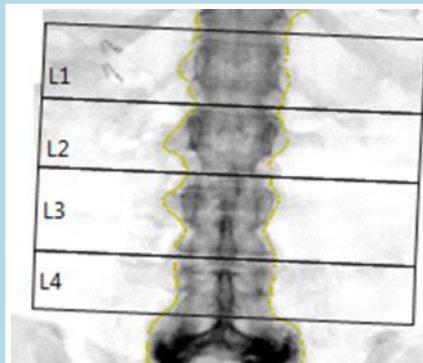
DXA results showed normal BMD T-score values at the spine, and lowest value at the femur was right femoral neck T-score -1.1. These stress fracture sites are not considered usual 'osteoporotic' fracture sites, so FRAX® may be used as a guideline for treatment. Her FRAX 10-year probably of fracture was low with major osteoporotic risk of 12.6 % and hip fracture risk of 0.8 %, and this is including 'previous fracture'.

Her Trabecular Bone Score value, however, was very low at 1.137.

■ Bone Assessment & Analysis Images

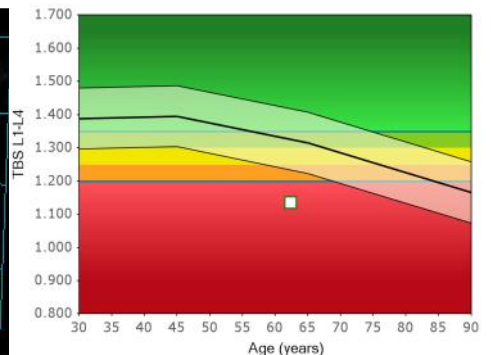
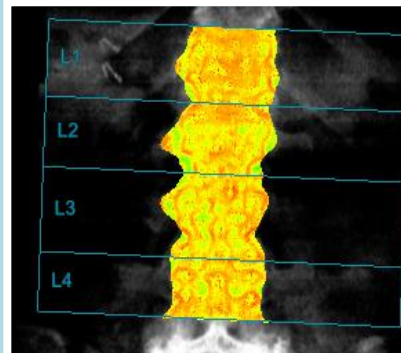
Normal BMD

Spine T-Score (L1-L4): -0,4



Low TBS value

Spine TBS (L1-L4): 1,137



■ Conclusion & Patient Management Decision

In view of the low Trabecular Bone Score we felt that future fracture risk was significantly higher than reflected by BMD values alone and FRAX® calculation, and the patient was started on active therapy with a plan to follow DXA and TBS.

70-year Old Woman 2 years Follow-up Results



By Dr Luis Del Rio and Dr Silvana Di Gregorio
CETIR Grup Medic, Barcelona, Spain (1/2)

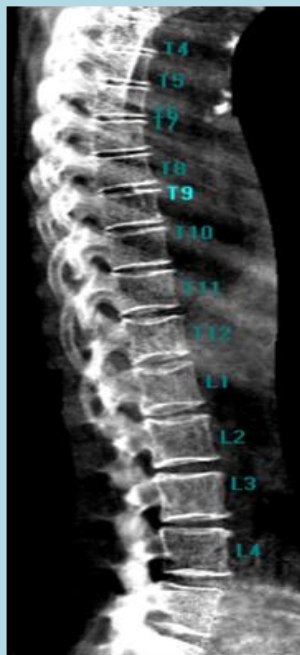

■ Patient Clinical Background

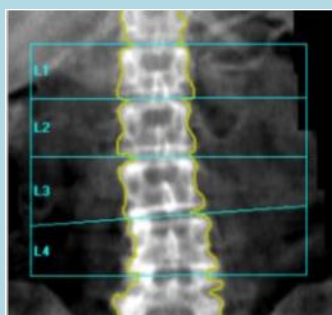
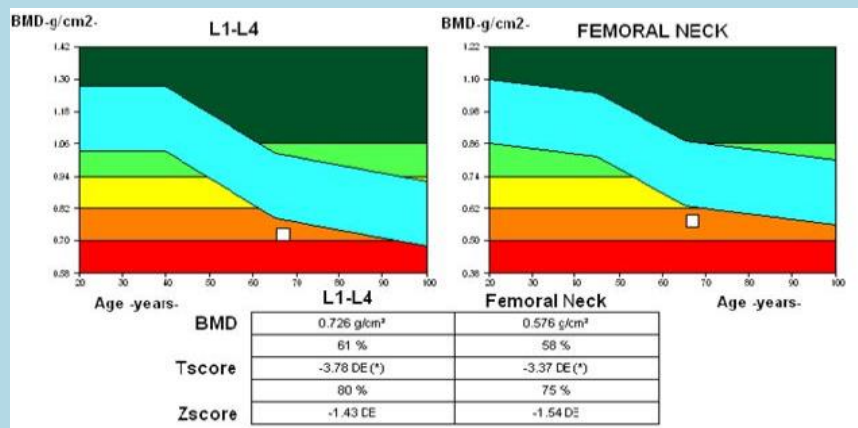
We describe the case of a 70-year old woman, menopause at 47 years. Neither history of any pathological condition that affect bone metabolism nor family fracture history was recorded. A bone densitometry scan was performed in March 2011 (Weight: 54kg; Height: 158 cm).

Lumbar spine and upper right femur were scanned and we included a lateral view of the total spine (LVA) due to low BMD results from lumbar spine scan.

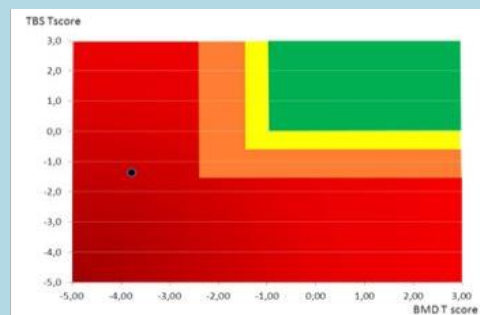
■ Bone Assessment & Analysis Images



LVA:
No observed height loss in vertebral bodies at T4-L4 region suggesting deformities or fractures.



BMD:
Lumbar Spine showed light degenerative changes.

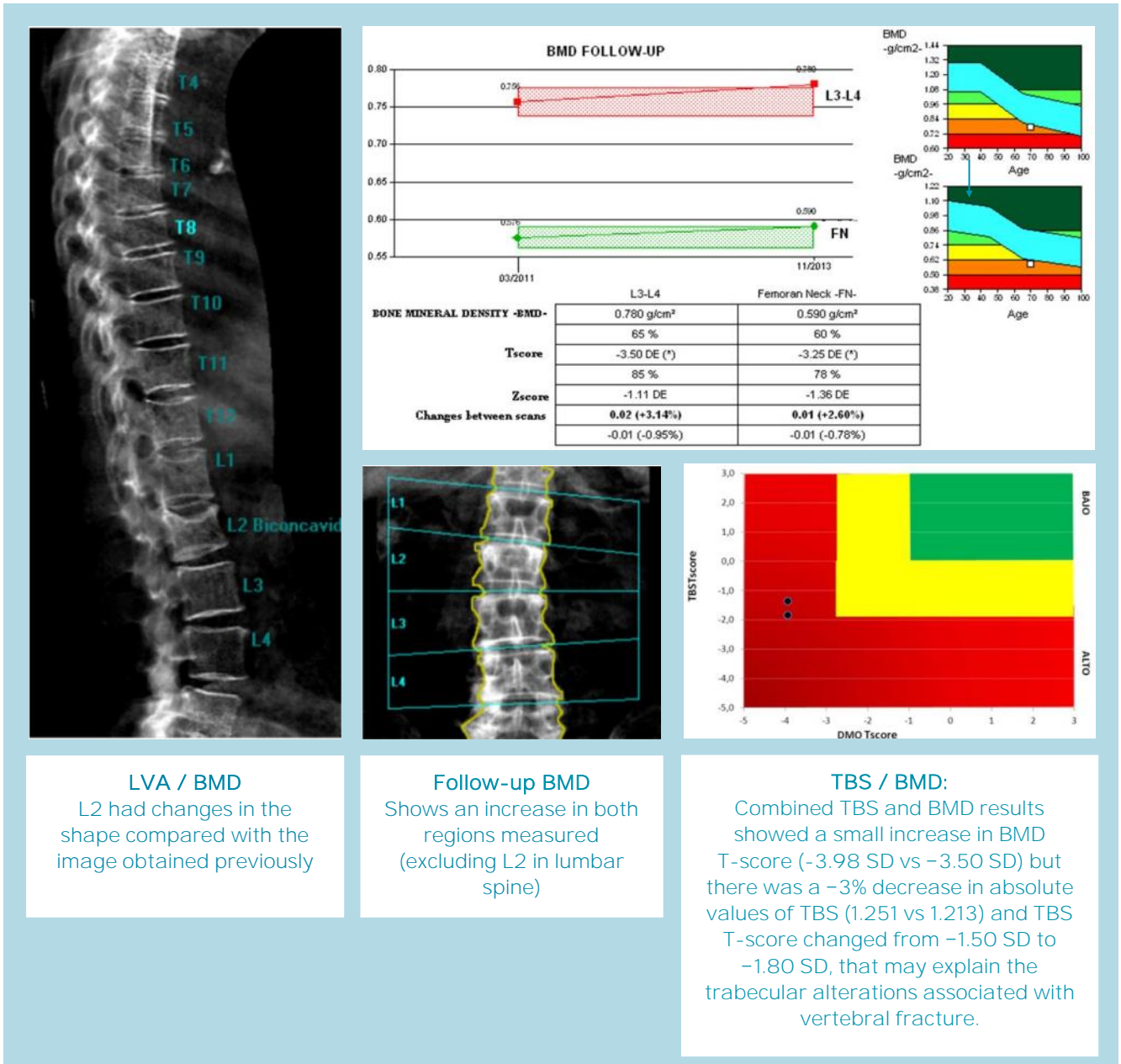


TBS / BMD:
Combined TBS and BMD results are in the zone of high compromise in bone structure and density.

Age of the patient and her low BMD were the main reasons to recommend an antiresorptive treatment with alendronate and a supplement of vitamin D (800 UI)

She came back for control after 2 years. Weight and height were similar (Weight: 55kg; Height: 158cm), she did not suffer any fall in the meantime. A DXA scan was performed and changes in the image of L2 at lumbar spine were noted.

A new LVA was also acquired. The lumbar spine BMD (excluding L2) showed an increase (+3.14%), as well as in the femoral neck (+2.60%) with respect to initial scans.



LVA / BMD
L2 had changes in the shape compared with the image obtained previously

Follow-up BMD
Shows an increase in both regions measured (excluding L2 in lumbar spine)

TBS / BMD:
Combined TBS and BMD results showed a small increase in BMD T-score (-3.98 SD vs -3.50 SD) but there was a -3% decrease in absolute values of TBS (1.251 vs 1.213) and TBS T-score changed from -1.50 SD to -1.80 SD, that may explain the trabecular alterations associated with vertebral fracture.

Conclusion & Patient Management Decision:

The TBS was a more reliable parameter than BMD to determine the real status of bone strength. If patient were evaluated with BMD only, the interpretation of the treatment response would have been positive, but in this case, the TBS was a better prognostic factor for the clinical outcome.

65-year Old Woman Osteopenic BMD–Low TBS



Dr Neil Binkley, Geriatrics

University of Wisconsin Hospital and Clinics, Madison, WI, USA (1/2)



■ Patient Clinical Background

Jane Doe is a 65-year old white female who is concerned about fracture risk, as her mother recently fell and sustained a hip fracture. Her mother had previously sustained three vertebral fractures, the first of which occurred at age 68. Ms. Doe is generally healthy, taking only a statin for hyperlipidemia. Her diet provides ~1,000 mg of calcium and she takes 1,000 IU of supplemental vitamin D₃ daily. She does not smoke, drinks one glass of wine daily and walks for ~30 minutes three to five times a week. Her menopause was at age 48, and she never received estrogen therapy. She has no personal history of fragility fracture, rheumatoid arthritis or glucocorticoid use.

Her physical examination is unrevealing: height is 5'2 and weight 126 pounds.

Laboratory evaluation included serum calcium, creatinine, phosphorous, PTH, and 25 (OH)D, all of which were normal.

■ Bone Assessment & Analysis Images

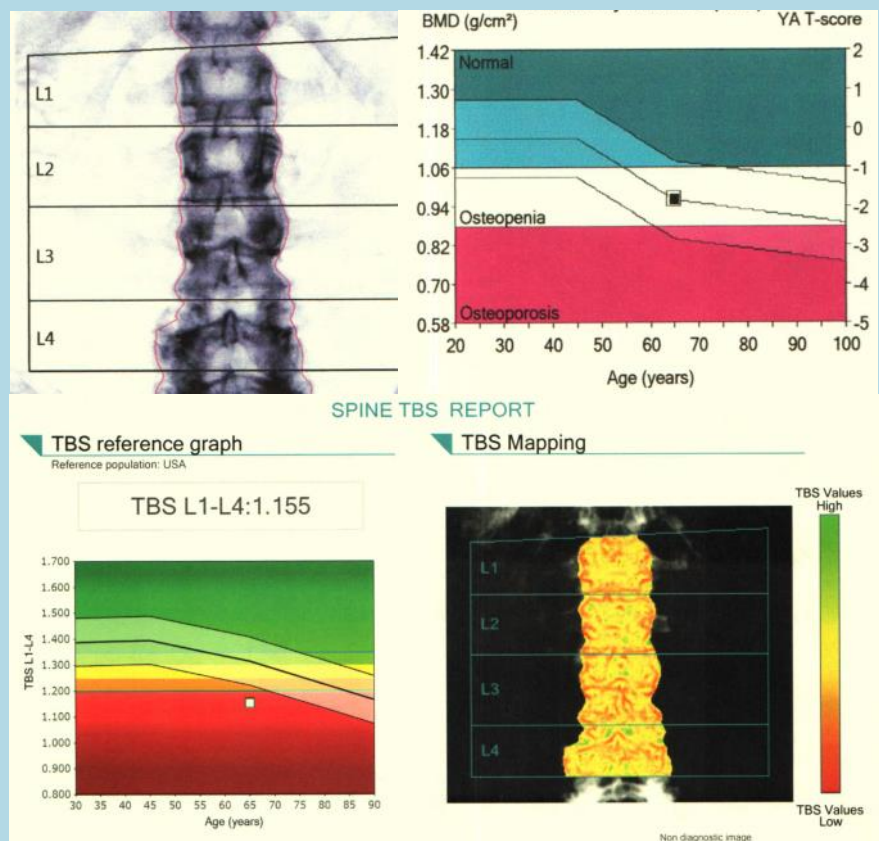
Osteopenic BMD

Spine T-Score (L1-L4): -1.8

Left Femoral Neck T-score: -1.7

Low TBS value

Spine TBS (L1-L4): 1.155



FRAX® 10-year & FRAX Adjusted for TBS Assessment

Country: US (Caucasian) Name/ID:

Questionnaire:

1. Age (between 40 and 90 years) or Date of Birth
 Age: Date of Birth: Y: M: D:

2. Sex Male Female

3. Weight (kg)

4. Height (cm)

5. Previous Fracture No Yes

6. Parent Fractured Hip No Yes

7. Current Smoking No Yes

8. Glucocorticoids No Yes

9. Rheumatoid arthritis No Yes

10. Secondary osteoporosis No Yes

11. Alcohol 3 or more units/day No Yes

12. Femoral neck BMD (g/cm²)
 T-score: -1.7

BMI: 23.0
 The ten year probability of fracture (%)
with BMD

Major osteoporotic	18
Hip Fracture	1.2

If you have a TBS value, click here:



The 10 year probability of fracture (%)
 Adjusted for TBS

Major Osteoporotic Fracture :	21
Hip Fracture :	1.7

Conclusion & Patient Management Decision

In this individual, the estimated 10-year probability of major osteoporosis related fracture is 18%.

Based on this, she does not meet current NOF guidelines for therapy.

However, her TBS is 1.155.

The 10-year probability of major osteoporotic related fracture adjusted for TBS is 21%. Based upon this, she does meet treatment guidelines.

To learn more about TBS iNsight, please review our white papers:

- *Advanced DXA Using TBS iNsight™*
- *TBS iNsight™ : A Useful Tool to Potentially Reconsider Patient Fracture Risk.*
- *FRAX Adjusted for TBS.*

Medimaps Group Headquarters:
18 chemin des Aulx,
CH-1228 Plan-les-Ouates
(Geneva) - Switzerland
Tel. +41 22 884 86 44

Medimaps Group USA:
63 Stratford Road
Needham, MA 02492
Tel. +1.800.321.4472

contact@medimapsgroup.com
www.medimapsgroup.com

TBS iNsight is a trademark of Medimaps Group. All other trademarks, registered trademarks and product names are the property of their respective owners.

This information is intended for educational purposes, as well as medical professionals in the U.S. and other markets and is not intended as a product solicitation or promotion where such activities are prohibited.

For information on what products are available for sale and in which country, please contact us at contact@medimapsgroup.com