



Compendium of TBS Clinical Case Studies

bone structure matters

Compendium of TBS Clinical Case Studies

Medimaps Group thank all the authors for their contribution.

TBS iNsite™ is a software program to evaluate bone microarchitecture in clinical practice and enhance fracture risk prediction.

TBS is an independent risk of fracture and therefore an additional clinical risk factor. As such, it should be interpreted in accordance with appropriate guidelines and according to the good practice – as defined in the Position Development Statements of the International Society for Clinical Densitometry (ISCD).

This document contains clinical cases provided by physicians using TBS iNsite in their practice. As such, it reflects their own clinical experience and should not serve as medical instructions. Only the healthcare professionals can take medical decisions based on clinical judgment and on all available clinical information.

Compendium of TBS Clinical Case Studies first edition: March 2016

MM-BR-097-MIG-EN-01

Table of Contents

■ TBS & Patient Management

Case 1	Dr Gerardo Aguilar 63-year old woman with osteopenic BMD—low TBS	04
Case 2	Dr Gerardo Aguilar 67-year old woman with osteopenic BMD—low TBS	05
Case 3	Dr Laure Chapuis 69-year old woman with osteoporotic BMD—high TBS	07
Case 4	Dr Christine Simonelli Interview & Clinical case 62-year old woman with normal BMD—low TBS	09
Case 5	Dr Fabio Massimo Ulivieri Interview & Clinical case 59-year old woman with osteopenic BMD—low TBS	12
Case 6	Dr Luis Del Rio & Dr Silvana Di Gregorio 70-year old woman & 2 years follow-up results	14

■ TBS & Secondary Osteoporosis

Case 7	Dr Laure Chapuis 70-year old woman with primary hyperparathyroidism	16
Case 8	Dr Bérengère Aubry-Rozier & Dr Olivier Lamy 54-year old woman with breast cancer & anti aromatase therapy	18

■ FRAX Adjusted for TBS

Case 9	Dr Andrew J. Laster 57-year old woman with osteoporotic BMD—low TBS	20
Case 10	Dr Neil Binkley 65-year old woman with osteopenic BMD—low TBS	22

63-year Old Woman Osteopenic BMD–Low TBS



By Dr Gerardo Aguilar, General Practitioner & Clinical Densitometrist
Clinica Bajío Clinba, Guanajuato, México.

Patient Clinical Background

This is a 63-year old woman who was referred for bone density testing, with the following important medical backgrounds: mother with forearm history fracture, no previous fracture, regular calcium and vitamin D intake, hysterectomy at age 41 (no oophorectomy).

Bone Assessment & Analysis Images

Osteopenic Spine BMD

Spine T-Score (L1-L4): -1.4

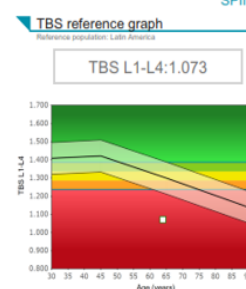
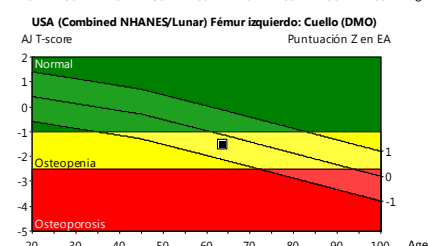
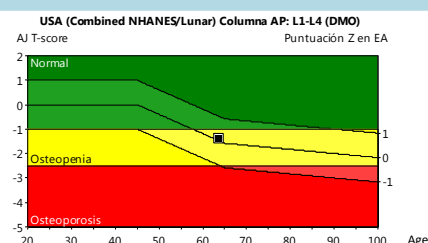
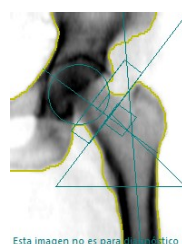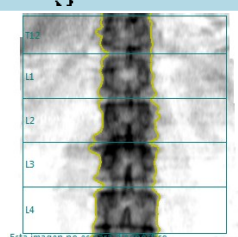
Osteopenic Femur BMD

Femoral Neck BMD T-score: -1.5

Total Hip BMD T-score: -1.3

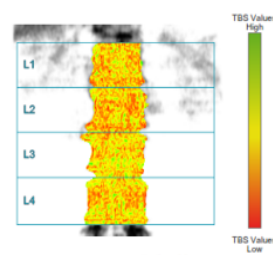
Low TBS value

Spine TBS (L1-L4): 1.073



SPINE TBS REPORT

TBS Mapping



Conclusion & Patient Management Decision:

FRAX® result: 4.7% for major osteoporotic fracture, 0.8% for hip fracture.

CAROC assessment: Low risk fracture.

However TBS score was reported as degraded (below 1.200).

FRAX® Adjusted for TBS: 7.5% for major osteoporotic fracture; 1.52% for hip fracture.

Based on clinical risk fracture of the patient our recommendation was to assure an adequate calcium intake as well as Vitamin D, and a training exercise for bone strength.

Referral physician decided to start anti-resorptive treatment (Risedronate 5mg daily).

67-year Old Woman Osteopenic BMD–Low TBS



By Dr Gerardo Aguilar, General Practitioner & Clinical Densitometrist
Clinica Bajío Clinba, Guanajuato, México (1/2)

Patient Clinical Background & Clinical Assessment

This is a 67-year old woman who was referred to our clinic for bone density testing.

Important background records were: hysterectomy (without oophorectomy), omeprazole use sporadically, height loss and a metatarsal fracture 5 years ago.

No diabetic or other comorbidities.

Bone Assessment & Analysis Images

Osteopenic Spine BMD

Spine T-Score (L1-L4): -1.1

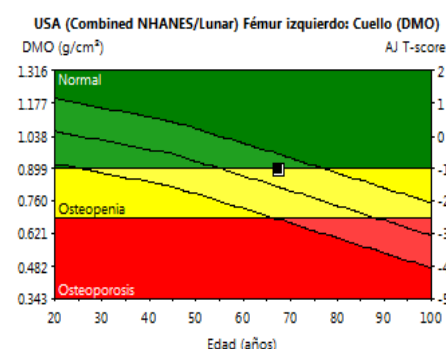
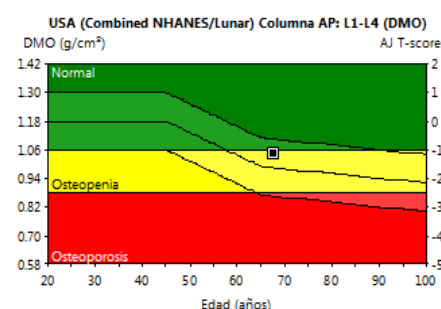
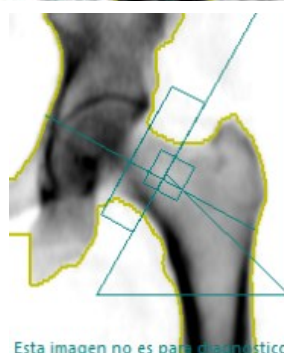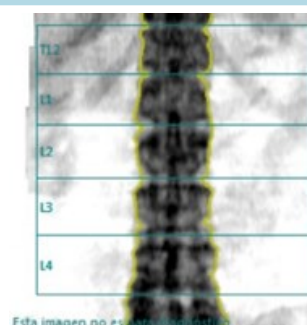
Normal Femur BMD

Femoral Neck BMD T-score: -1.0

Total Hip BMD T-score: 0.1

Low TBS value

Spine TBS (L1-L4): 1.064

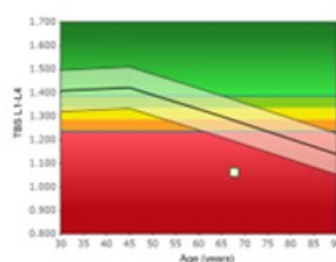


SPINE TBS REPORT

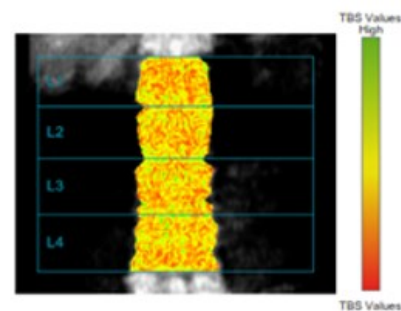
TBS reference graph

Reference population: Latin America

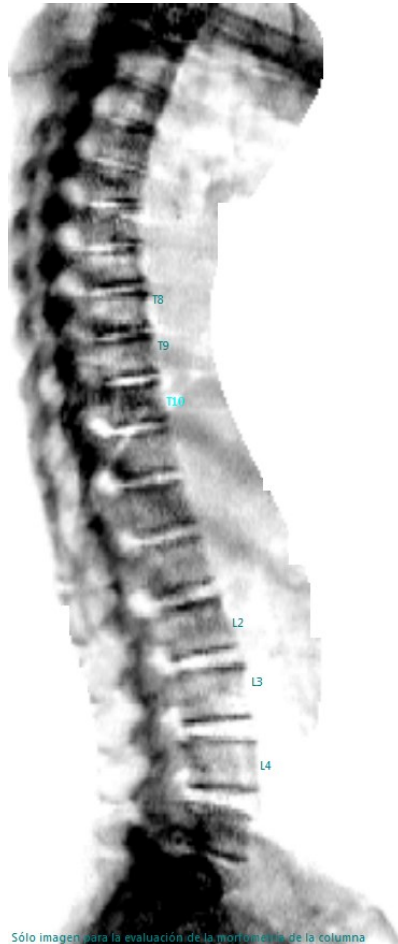TBS L1-L4: 1.064



TBS Mapping



■ Vertebral Fracture Assessment



Date of birth	10/09/1946
Age	67.6 y
Height / Weight	157.0 cm / 70.4 kg
Ethnicity	Hispanic

		Alt. Med.		Coeficiente A/P	
	Region	(cm)	Z-score	(%)	Z-score
	T8	1.49	-0.5	99	1.3
	T9	1.51	-0.8	106	2.1
	T10	1.57	-1.1	95	0.1
	L2	2.23	0.2	108	1.3
	L3	2.26	0.1	106	0.8
	L4	2.19	-0.3	100	-0.8

■ Conclusion & Patient Management Decision

According to patient age and previously reported metatarsian fracture, patient was originally classified in moderate risk for fracture; but due to the TBS result and the results of the VFA & history of height loss, the patient was considered to be at higher risk for fracture and pharmacological treatment was indicated.

69-year Old Woman Osteoporotic BMD–High TBS



By Dr Laure Chapuis, Rheumatologist
Hospital of Vitré, Rennes, France (1/2)



■ Patient Clinical Background

Age: 69

Age of menopause: 50

Height: 158,5cm

Weight: 41 Kg

Bone treatment: Fosavance® for 8 years; stopped in 2011; then Prolia® started in October 2012 until now: 6 injections in total

History of fragility fracture: 0

VFA examination: no fracture

Fall in last 12 months: 1

Known risk factors: parental history of femoral neck fracture; IMC< 19 (16.3 at exam date);

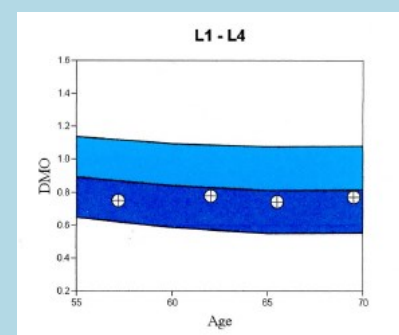
New risk factors: 0

■ Bone Assessment & Analysis Images

Spine BMD follow-up Examination:

Résumé des résultats DXA : L1 à L4

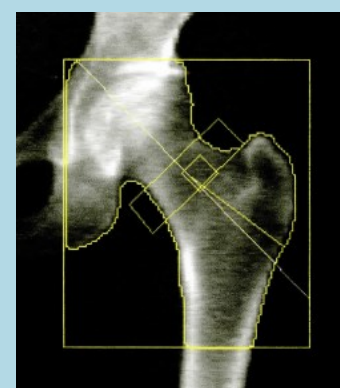
Date d'Examen	Age	DMO (g/cm ²)	T - score
17.10.2015	69	0.771	-2.3
15.10.2011	65	0.744	-2.5
24.04.2008	62	0.777	-2.2
25.06.2003	57	0.750	-2.5



Hip BMD follow-up Examination:

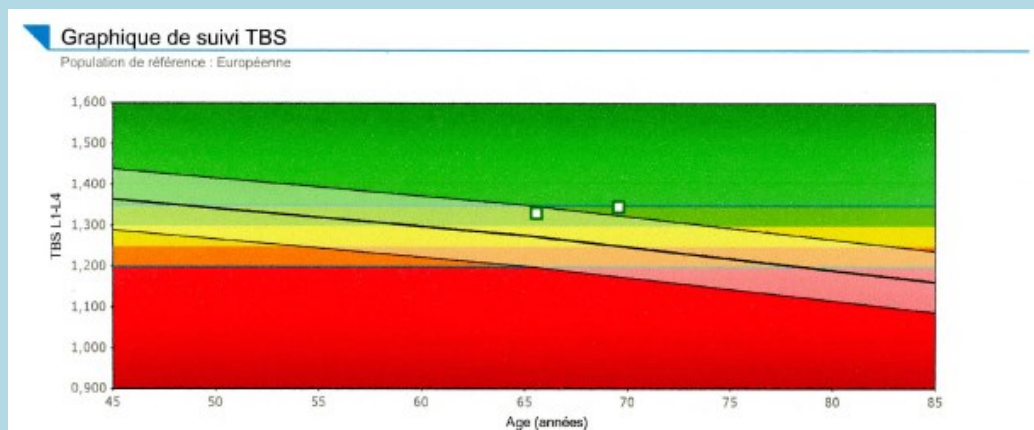
Résumé des résultats DXA :

Date d'Examen	Age	DMO (g/cm ²)	T - score
17.10.2015	69	0.772	-1.3
15.10.2011	65	0.780	-1.2
24.04.2008	62	0.748	-1.5
25.06.2003	57	0.710	-1.8



TBS follow-up Examination :

Résultats du suivi		
Date examen	Age	TBS L1-L4
15/10/2011	66	1,332
17/10/2015	70	1,348



Conclusion & Patient Management Decision:

Decision is made to stop Prolia® in accordance with the French GRIO recommendations to take a pause in long therapeutic treatment.

A control visit and exam will be made in 2 years.

The example shows that TBS is sensitive and improved by the treatment.

Fosavance® is a registered trademark of MSD; active molecules: alendronic acid and colecalciferol; tablet.
Prolia® is a registered trademark of Amgen; active molecule: denosumab; injection.

Interview & Clinical case

62-year Old Woman

Normal BMD–Low TBS



*By Dr Christine Simonelli,
Board Certified in Internal Medicine and Clinical Densitometrist
HealthEast Osteoporosis Care, Greater Minneapolis, MN, USA (1/3)*



Interview:

Medimaps Group: From your activity within HealthEast Clinics, the ISCD and Own the Bone, you have a great experience in Osteoporosis Management. Would you share with us your feedback on TBS and what it brings to clinicians for osteoporosis management?

Dr Simonelli: I am very happy you ask the question, because I have been using TBS for a year now and I think it is a great tool! In my practice TBS is very useful during the whole patient management process, helping in decision making for diagnosis, treatment and patients' follow-up care.

I analyze the TBS of all eligible patients. It enables me to complete the diagnosis by adding an estimation of bone microarchitecture to the tools we are already using the estimation of density (BMD) and estimation of future fracture (FRAX®) for our low bone density patients.

When the diagnosis of a patient's bone status is clear, TBS is reassuring. When you have cases where the decision to treat or not is equivocal, which we often do, TBS clearly brings added valuable information to identify patients at risk. It helps a lot in cases where the bone density measurement with DXA may not be telling the whole story, such as in patients with diabetes or those using glucocorticoids. The Trabecular Bone Score adds to the assessment of bone strength in these patients.

M.G.: This is very interesting. What about treatment and patient follow-up?

Dr Simonelli: TBS helps to identify patients with degraded bone structure who are therefore more likely to break a bone. Knowing the TBS of my patient helps me to decide to initiate treatment and then to select the most appropriate treatment. The effects on bone structure differ from one treatment to another (Ex: bisphosphonates vs. Denosumab), so knowing the TBS helps in my selection of drug therapy.

Compliance and adherence with the selected treatment is also critical and needs to be monitored closely. The TBS is useful in following the patient's progress over time, and it is a tool that allows me to verify the impact of the selected treatment on a patient's bone structure. It allows me to adapt treatment according to the evolution of my patient's TBS.

A TBS follow-up examination after 2 years of treatment helps me reevaluate my treatment choice. For example, it is an added tool in deciding on a drug holiday in selected patients if the TBS has increased, or to continue with my treatment if a positive effect is observed in a high risk patient. It can direct me to a change in therapy if no positive effect on bone structure is noted.

Dr Christine Simonelli – Interview (2/3)

M.G.: You have been working with TBS and presented several studies already. Would you like to tell us what you have been focusing on and what were your findings?

Dr Simonelli: We have been working on the American Caucasian-Women reference curve, and have in a second study compared the values of this curve to the ones of the existing European curve [this was part of the ASBMR 2013 scientific program].

From our database, we have analyzed TBS values to subcategorize patients and define TBS thresholds for patient management. Using this curve makes it very easy to interpret TBS in daily practice, since we now can compare our patients to the "normal" population.

M.G.: Was it easy for you to integrate TBS iNsight® into your center, and is it easy to use?

Dr Simonelli: Yes it is a very easy-to-use software program, and most importantly, it is very easy to interpret and incorporate into a clinically useful DXA report. At HealthEast, the TBS analysis is done on every scan being done on a post-menopausal woman and reports are provided to the ordering physician and to the patient.

M.G.: Thank you, Christine. We understand that TBS is very useful for patient management. Would you say it is a useful innovation in the bone densitometry field?

Dr Simonelli: TBS compliments the existing equipment that we are currently using. Bone densitometry technology is continuing to advance, but DXA gives estimation of calculated volumetric bone density by giving us an areal measure. With TBS on our DXA equipment, we can now benefit from an estimation of the bone microarchitecture at the same time that we perform bone density testing with DXA. So yes, I would say it is a great innovation in the field of bone assessment.

M.G.: TBS "examination" just takes a few seconds, but is not reimbursed yet. Would you still recommend using it? Do you think it should be reimbursed in the near future?

Dr Simonelli: TBS gives us significant added-value information and it is time to start asking for reimbursement.

I don't believe our patients should pay any additional fee to benefit from advanced technologies for their examination. So reimbursement for TBS as an important tool giving us important information to use in the evaluation and management of the patient would indeed be appropriate.

M.G.: You may want to share some clinical cases you encountered that illustrate TBS added-value for the diagnosis, understanding and management of your patients' disease, or treatment selection and follow-up?

Dr Simonelli: Yes, sure

Check the selected clinical case of Christine next page.

M.G.: Of course, if there is any comment you would like to add, please feel free.

Dr Simonelli: Using the TBS software and showing TBS reports to my patients is an important tool to help our patients understand the need to accept a treatment. Compliance with osteoporosis therapy is a big problem and as a silent disease until a fracture occurs, we need clear evidence to help our patients understand the need for pharmaceutical therapy when they are feeling well. Demonstrating the TBS report is an important tool to help our patients understand this need by understanding their disease better.

I also believe that it is a priority for centers of excellence providing osteoporosis care to utilize the highest quality diagnostic tools to help care for our patients, including the trabecular bone score. That is why we are using highest standard and up-to-date technologies.

TBS has been a worthwhile investment for our medical center and osteoporosis service.

■ Patient Clinical Background

This is a 62-year old woman who was referred for bone density testing and evaluation because of multiple stress fractures of the metatarsals and fibula. The participant had a history of hysterectomy with bilateral oophorectomy and was on estrogen supplementation as her only prescription medication. She had just been started on calcium and vitamin D by her primary physician.

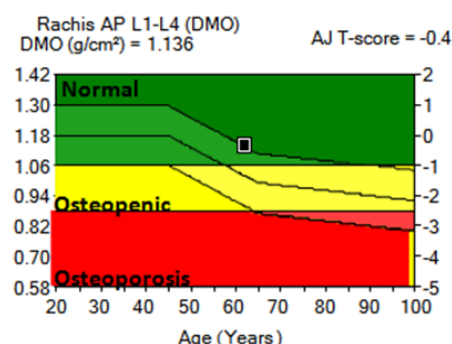
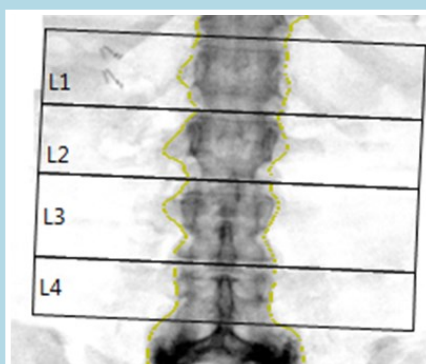
DXA results showed normal BMD T-score values at the spine, and lowest value at the femur was right femoral neck T-score -1.1. These stress fracture sites are not considered usual 'osteoporotic' fracture sites, so FRAX® may be used as a guideline for treatment. Her FRAX 10-year probability of fracture was low with major osteoporotic risk of 12.6 % and hip fracture risk of 0.8 %, and this is including 'previous fracture'.

Her Trabecular Bone Score value, however, was very low at 1.137.

■ Bone Assessment & Analysis Images

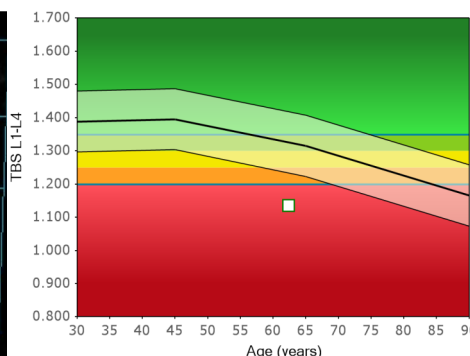
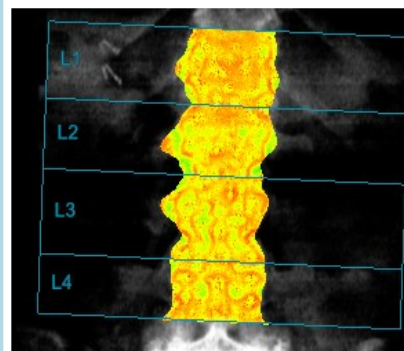
Normal BMD

Spine T-Score (L1-L4): -0.4



Low TBS value

Spine TBS (L1-L4): 1.137



■ Conclusion & Patient Management Decision

In view of the low Trabecular Bone Score we felt that future fracture risk was significantly higher than reflected by BMD values alone and FRAX® calculation, and the patient was started on active therapy with a plan to follow DXA and TBS.

Interview & Clinical case 59-year Old Woman Osteopenic BMD–Low TBS



By Dr Fabio Massimo Ulivieri, MD, Italy (1/2)



Interview:

Medimaps Group: Can you say a few words about your published study on TBS for our readers?

Dr Ulivieri: Patients with adrenal incidentalomas and subclinical hypercortisolism are at risk of fracture independently of bone mineral density and possibly due to reduced bone quality. Scarce data are available regarding the use of TBS in patients with glucocorticoid* induced osteoporosis and no study evaluated its use in endogenous hypercortisolism.

For these reasons we have studied subclinical hypercortisolism using TBS tool. Our data suggest that in subclinical hypercortisolism bone microarchitecture, as measured by TBS, is altered and TBS is useful in detecting patients with adrenal incidentalomas at risk of fractures.

M.G.: Do you use TBS routinely?

Dr Ulivieri: Yes. I use TBS routinely in my bone metabolic unit. All DXA lumbar scans are accompanied by TBS results.

M.G.: How would you describe TBS in a few words, and what is TBS added value according to you?

Dr Ulivieri: TBS brings a relevant information about bone quality, calculated from the 2D projection images acquired during a DXA lumbar Spine scan. TBS is used in addition to BMD to subcategorize patients according to their level of risk. As demonstrated by numerous studies, TBS is strongly correlated with bone microarchitecture, regardless of BMD. That is why TBS is bringing valuable information in bone mineral densitometry for fracture risk assessment in postmenopausal osteoporosis.

M.G.: Since you use TBS in your clinical practice, have you noticed a change in your diagnosis and medical decision?

Dr Ulivieri: In my daily practice, TBS is a useful tool to assess fracture risk in patients with normal or low BMD and one or more clinical risk factors. We observed that patients with low BMD and low TBS present more likely fractures than patients with low BMD but high TBS.

I recommend to perform TBS during all the lumbar DXA scans and to pay attention when a patient presents normal BMD and low TBS. I also recommend to include in DXA report TBS data to improve BMD measurement interpretation.

M.G.: Could you give us an example of a patient that illustrates TBS added value in your practice?

Dr Ulivieri: I have selected this patient case, as we understand that with TBS indicating a strong degradation of the bone microarchitecture status, we may consider treatment options. That would have been excluded without TBS. Indeed, I have particular attention to evaluate treatment options in patients with normal bone mineral density and low or very low TBS.

M.G.: As you know, TBS is getting widely used. As one of the first users in Italy, what would you like to say about TBS?

Dr Ulivieri: I suggest my colleagues, who do not know about TBS, to read scientific literature about TBS in postmenopausal osteoporosis and to focus on correlations between TBS results and fracture risk as results are impressive.

**Editor's note: Dr Ulivieri was interviewed in January 2013, numerous data have been published since then and he participated in several of them*

■ Patient Clinical Background

Woman aged 59

Menopause at 54 years, no HRT (hormone replacement therapy)

Low calcium intake

Physical activity <3 hrs/week

BMD at baseline (2004): Normal

Back pain since 5 months

Lumbar spine X ray: no fracture

BMD in 2012: 10% reduction (fracture risk doubled)

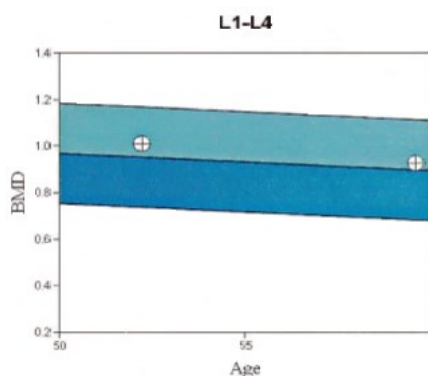
TBS deteriorated

Biochemical bone turn over markers: low vitamin D level (insufficiency).

Medical Decision Without TBS

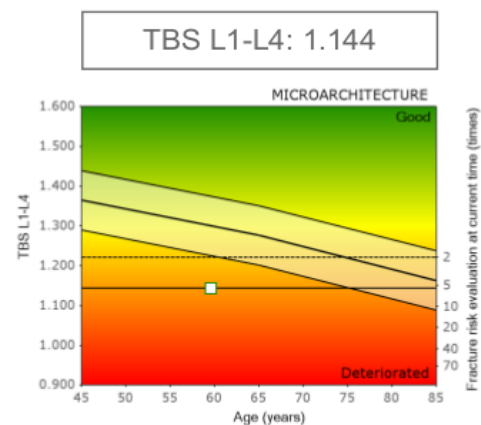
- Calcium and vitamin D
- Bone densitometry follow-up

BMD - **T-Score**
(g/cm²)
0,927 - **-1,1**



Medical Decision With TBS

- Calcium and vitamin D
- Pharmacological treatment
- Bone densitometry follow-up



■ Conclusion & Patient Management Decision


Based on BMD only, the authors would have prescribed calcium & vitamin D supplementation to the patient. TBS added the bone structure parameter to the equation and led the authors to decide to prescribe a pharmacological treatment in addition to calcium and vitamin D.

Dr Ulivieri was originally interviewed in January 2013 and his testimony was published in TBS Newsletter Winter 2013 Ed.

70-year Old Woman 2 years Follow-up Results



By Dr Luis Del Rio and Dr Silvana Di Gregorio
CETIR Grup Medic, Barcelona, Spain (1/2)

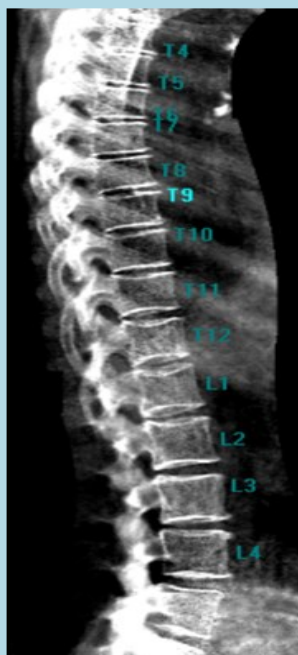

Patient Clinical Background

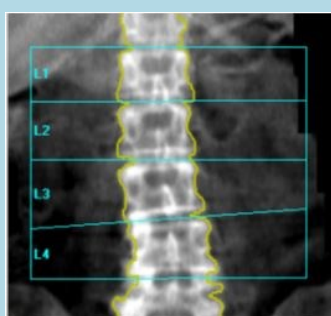
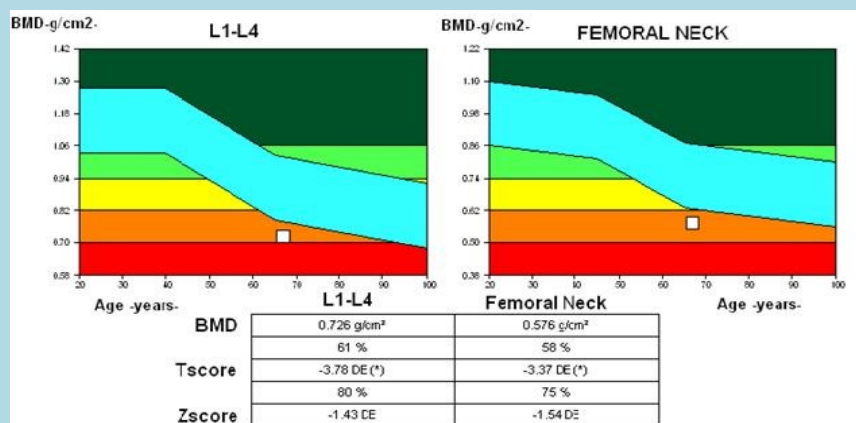
We describe the case of a 70-year old woman, menopause at 47 years. Neither history of any pathological condition that affect bone metabolism nor family fracture history was recorded. A bone densitometry scan was performed in March 2011 (Weight: 54kg; Height: 158 cm).

Lumbar spine and upper right femur were scanned and we included a lateral view of the total spine (LVA) due to low BMD results from lumbar spine scan.

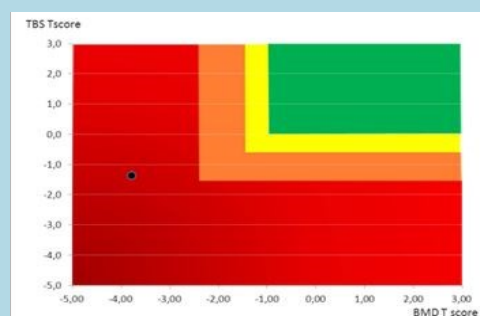
Bone Assessment & Analysis Images



LVA:
No observed height loss in vertebral bodies at T4-L4 region suggesting deformities or fractures.



BMD:
Lumbar Spine showed light degenerative changes.

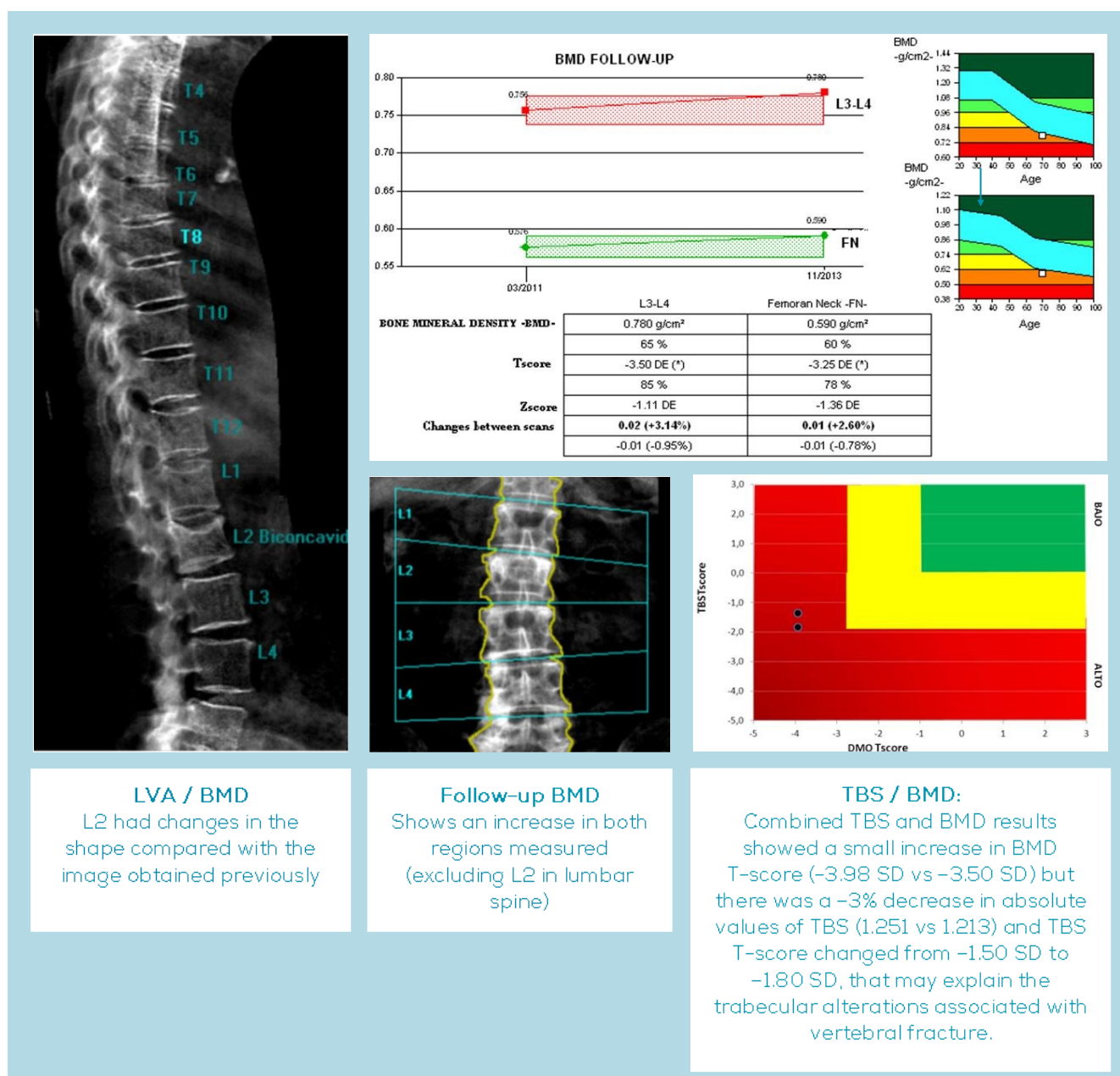


TBS / BMD:
Combined TBS and BMD results are in the zone of high compromise in bone structure and density.

Age of the patient and her low BMD were the main reasons to recommend an antiresorptive treatment with alendronate and a supplement of vitamin D (800 UI)

She came back for control after 2 years. Weight and height were similar (Weight: 55kg; Height: 158cm), she did not suffer any fall in the meantime. A DXA scan was performed and changes in the image of L2 at lumbar spine were noted.

A new LVA was also acquired. The lumbar spine BMD (excluding L2) showed an increase (+3.14%), as well as in the femoral neck (+2.60%) with respect to initial scans.



Conclusion & Patient Management Decision:

The TBS was a more reliable parameter than BMD to determine the real status of bone strength. If patient were evaluated with BMD only, the interpretation of the treatment response would have been positive, but in this case, the TBS was a better prognostic factor for the clinical outcome.

70-year Old Woman Primary Hyperparathyroidism

By Dr Laure Chapuis, Rheumatologist
Hospital of Vitré, Rennes, France (1/2)



■ Patient Clinical Background

Age: 70

Menopause at 55

Height: 147 cm

Weight: 60 Kg

Substitutive hormonal therapy: during 10 years; stopped

No bone treatment

History of fracture: 0

Fall in last 12 months: 0

Other risk factors: Primary hyperparathyroidism for 10 years with no indication for surgery (no apparent adenoma);

FRAX® 10-year fracture risk:

→ FRAX-MOF (major osteoporotic fracture): 7,5%

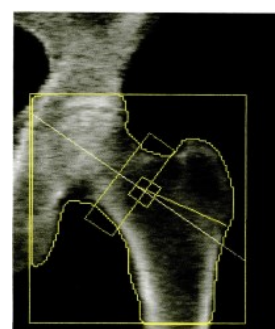
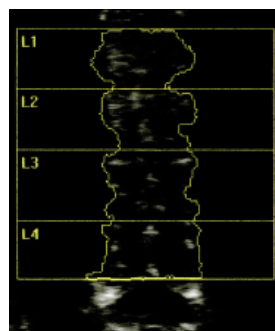
→ FRAX Adjusted for TBS – MOF: 13%

■ Bone Assessment & Analysis Images

Osteoporotic BMD

Spine T-score (L1-L4): -3,8

Hip Total T-score: -2

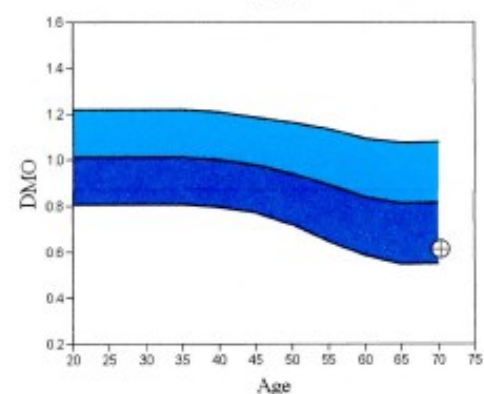


Résumé des résultats DXA :

Région	Surface (cm²)	CMO (g)	DMO (g/cm³)	T-score	PR (%)	Z-score	MA (%)
L1	9.93	6.54	0.659	-3.0	67	-1.1	84
L2	10.29	6.85	0.666	-3.1	66		
L3	12.26	6.99	0.571	-4.4	55		
L4	11.43	6.47	0.566	-4.5	53	-2.2	70
Total	43.90	26.86	0.612	-3.8	61		

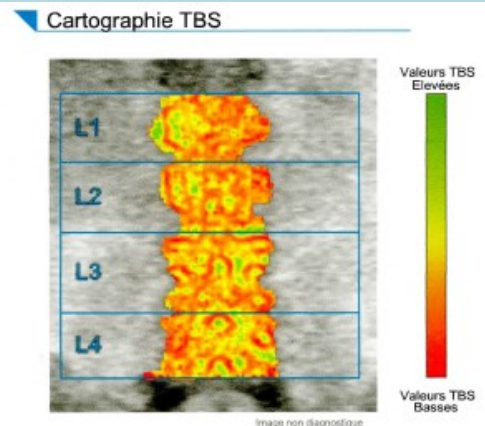
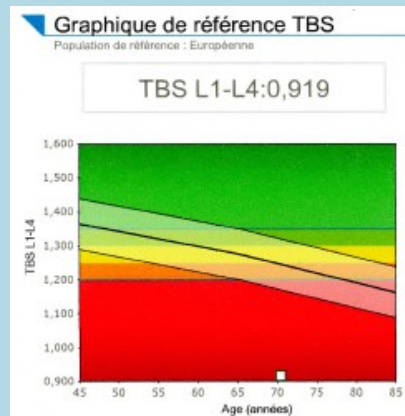
CV TOTALE DMO 1.0%, ACF = 1.019, BCF = 1.008, TH = 8.519

Total



Very low TBS:

Spine TBS (L1-L4): 0,919



FRAX 10-year & FRAX Adjusted for TBS Assessments:



10-year Fracture Risk¹:

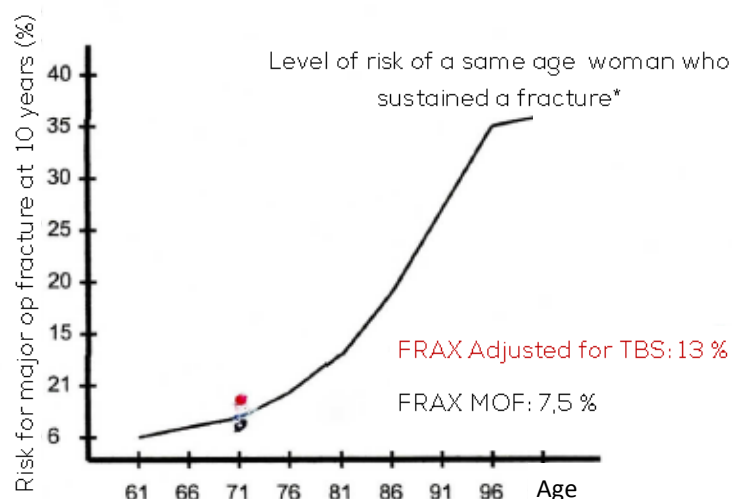
Major Osteoporotic Fracture	7.5%
Hip Fracture	2.2%

Reported Risk Factors:

France, T-score(WHO)=-2.1, BMI=27.8, secondary osteoporosis

The 10 year probability of fracture (%)
Adjusted for TBS

Major Osteoporotic Fracture : 13 %



Conclusion & Patient Management Decision

In this patient case, FRAX® is highly underestimated, as the lowest BMD measurement is of lumbar spine. TBS value is very low, therefore FRAX Adjusted for TBS is increased significantly, reflecting this highest risk. This leads to a change in the therapy and indication to go for surgery if possible for this patient.

In this case, TBS also replaces forearm measurement that is generally less reliable in case of osteoporosis with primary hyperparathyroidism.

* Intervention threshold based on the French « GRIO » recommendations.

54-year Old Woman Breast Cancer with Anti-aromatase Therapy



By Dr Bérengère Aubry-Rozier & Dr Olivier Lamy
CHUV - Lausanne (1/2)

■ Patient Clinical Background

54-year old woman diagnosed as osteoporotic by BMD during a control examination in the context of breast cancer monitoring protocol. The patient started anti-aromatase therapy, which led us to initiate a bone treatment by bisphosphonates.

Successive densitometry examinations showed a constant increase of the BMD results ; however, a progressive degradation of the bone texture is observed, as assessed by TBS; TBS values decrease from 1.211 to 1.142 and then to 1.097.

This patient case illustrates the negative impact of anti-aromatase on the bone texture and the absence of effect from bisphosphonates to slow down this degradation.

■ Bone Assessment & Analysis Images

Spine BMD follow-up Examination (T-score)

14.07.2010	-2.0
04.10.2013	-1.9
09.11.2015	-2.1

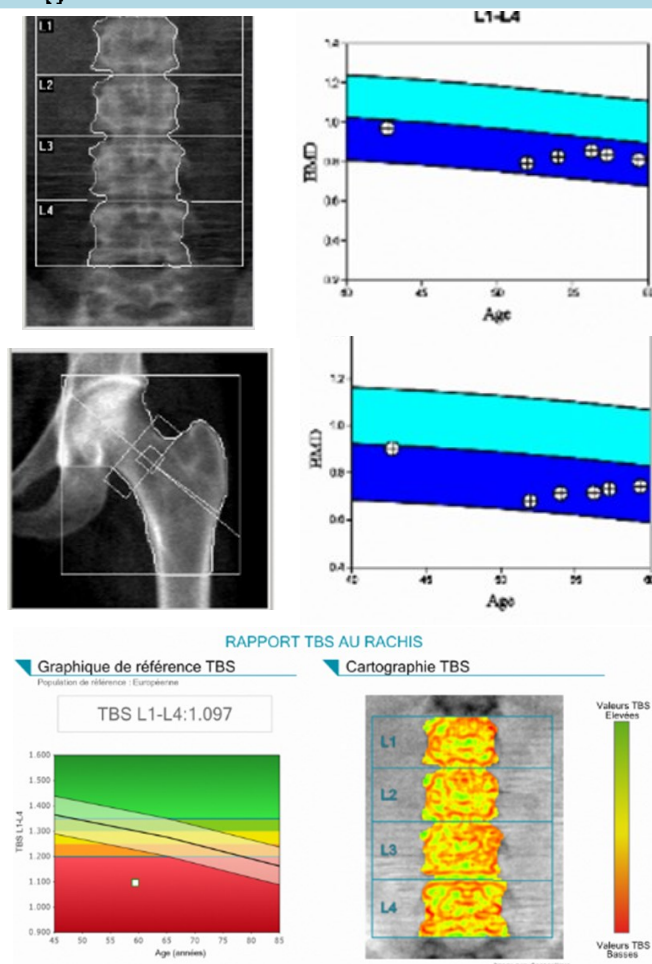
Hip BMD follow-up Examination

14.07.2010	-1.9
04.10.2013	-1.7
09.11.2015	-1.6

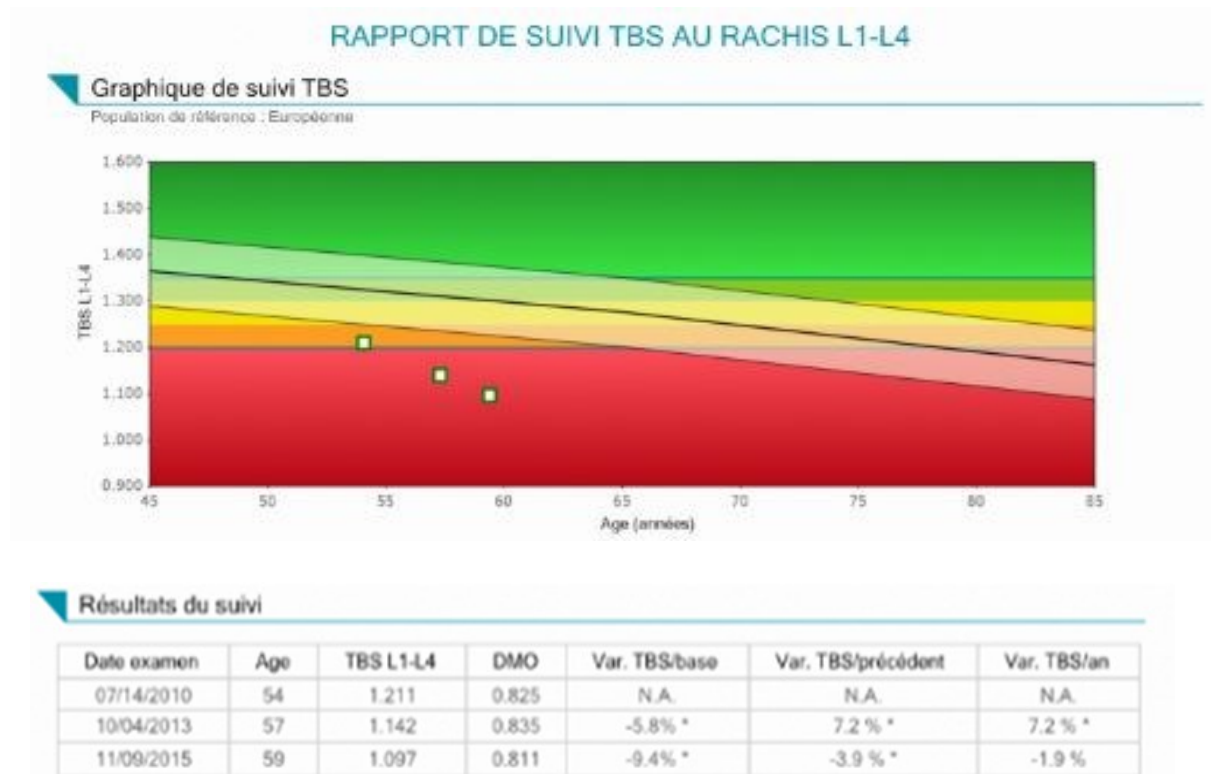
TBS

(absolute value)

14.07.2010	1.211
04.10.2013	1.142
09.11.2015	1.097



■ TBS Follow-up Examination :



■ Conclusion & Patient Management Decision

At the end of 5-year anti-aromatase therapy and 5-year bisphosphonates therapy without any observed incident fracture during this period, a close monitoring of TBS is proposed to the patient. We expect a significant improvement of TBS values in the coming years after the end of treatment. If however TBS value remains low, we will consider initiating a bone treatment with recognized impact on the bone texture.

57-year Old Woman Osteoporotic BMD—Low TBS



By Dr Andrew J. Laster, Rheumatologist
AOCC – Arthritis & Osteoporosis Consultants of the Carolinas
Charlotte, North Carolina 28 207, USA (1/2)



Patient Clinical Background

This is a 57-year old postmenopausal white female with a 12-year history of rheumatoid arthritis currently in remission on q eight-month IV rituximab, prednisone 5 mg QAM and diclofenac 75 mg daily. She was recently seen after sustaining bilateral low trauma forearm fractures when she tripped in church.

Her BMI is 23.9. She denies a history of prior fractures as an adult. She neither smokes nor drinks and has no other known risk factors for osteoporosis aside from nulliparity, rheumatoid arthritis and low-dose prednisone use. On exam she was noted to have lost 2" in height compared to known historical baseline. Her laboratory studies were significant only for an elevated CRP of 1.1 mg/deciliter. She had a normal CBC, chemistry profile, TSH, PTH, 25 OH vitamin D, SPEP, 24-hour urine calcium and urine N-telopeptide. No vertebral fractures were seen on VFA.

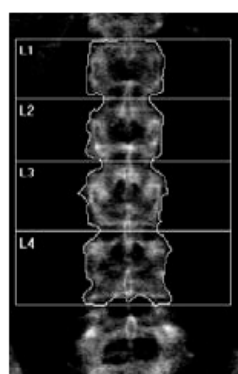
Bone Assessment & Analysis Images

Osteoporotic BMD

Spine T-Score (L1-L4): -3.2

Low TBS value

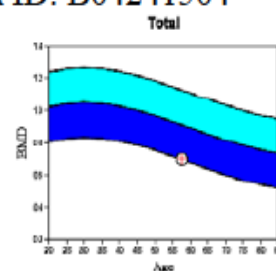
Spine TBS (L1-L4): 1.077



DAP: 4.2 cGy*cm²

Scan Date: April 24, 2015

Scan ID: B04241504



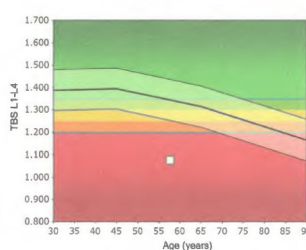
Scan Type: a Lumbar Spine

SPINE TBS REPORT

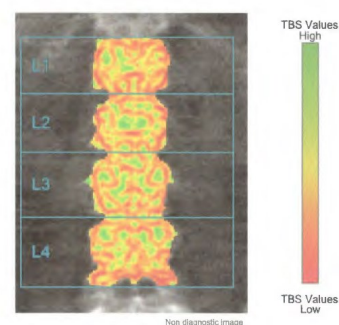
TBS reference graph

Reference population: USA

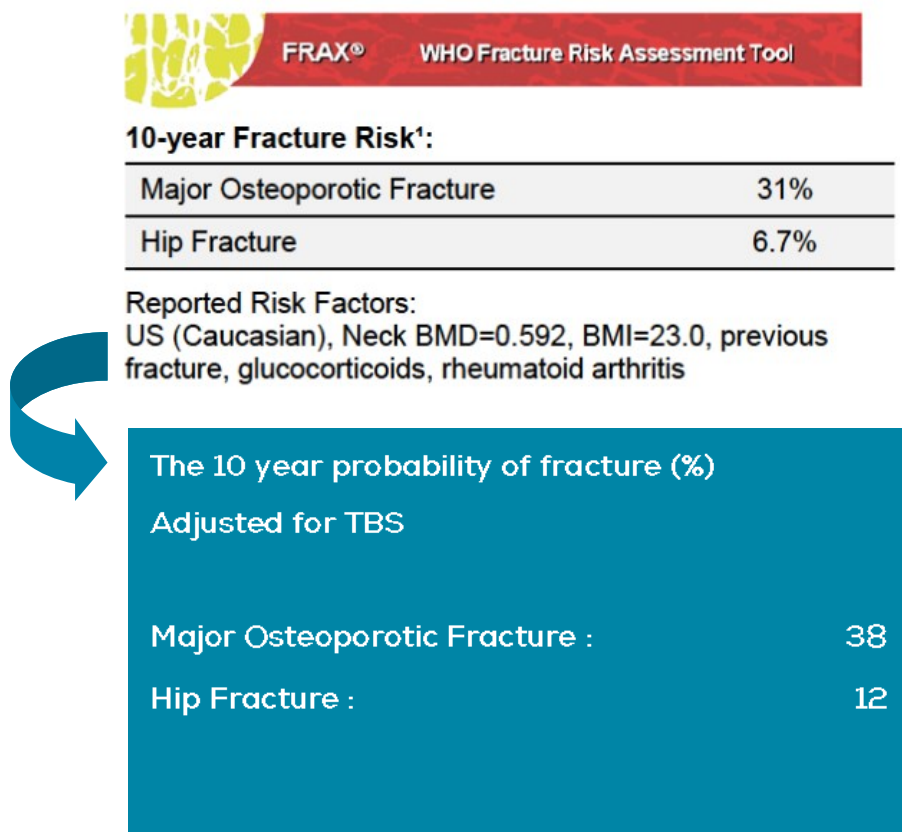
TBS L1-L4: 1.077



TBS Mapping



FRAX 10-year & FRAX Adjusted for TBS Assessments:



Conclusion & Patient Management Decision

The patient has osteoporosis based on recent fragility fractures of bilateral forearms. Her baseline DXA study shows densitometric evidence of osteoporosis with a lowest T-score of -3.2 in the lumbar spine. VFA did not identify any vertebral compression fractures. Risk factors include a history of rheumatoid arthritis, nulliparity and low-dose prednisone. No other secondary causes of metabolic bone disease were identified.

The profoundly low TBS results in a near doubling of the 10-year risk of hip fracture when TBS is modeled with FRAX® as compared to modeling with FRAX® alone (see above) in this individual. This finding reinforced the author's recommendation to initiate therapy with the only anabolic drug currently available in the USA, teriparatide 20 µg daily for two years. Based on the reported clinical and laboratory findings, her insurance company did not require prior treatment with an oral bisphosphonate or other parenteral drug therapies approved for the treatment of osteoporosis.

65-year Old Woman Osteopenic BMD–Low TBS



Dr Neil Binkley, Geriatrics

University of Wisconsin Hospital and Clinics, Madison, WI, USA (1/2)



■ Patient Clinical Background

Jane Doe is a 65-year old white female who is concerned about fracture risk, as her mother recently fell and sustained a hip fracture. Her mother had previously sustained three vertebral fractures, the first of which occurred at age 68. Ms. Doe is generally healthy, taking only a statin for hyperlipidemia. Her diet provides ~1,000 mg of calcium and she takes 1,000 IU of supplemental vitamin D₃ daily. She does not smoke, drinks one glass of wine daily and walks for ~30 minutes three to five times a week. Her menopause was at age 48, and she never received estrogen therapy. She has no personal history of fragility fracture, rheumatoid arthritis or glucocorticoid use.

Her physical examination is unrevealing: height is 5'2 and weight 126 pounds.

Laboratory evaluation included serum calcium, creatinine, phosphorous, PTH, and 25 (OH)D, all of which were normal.

■ Bone Assessment & Analysis Images

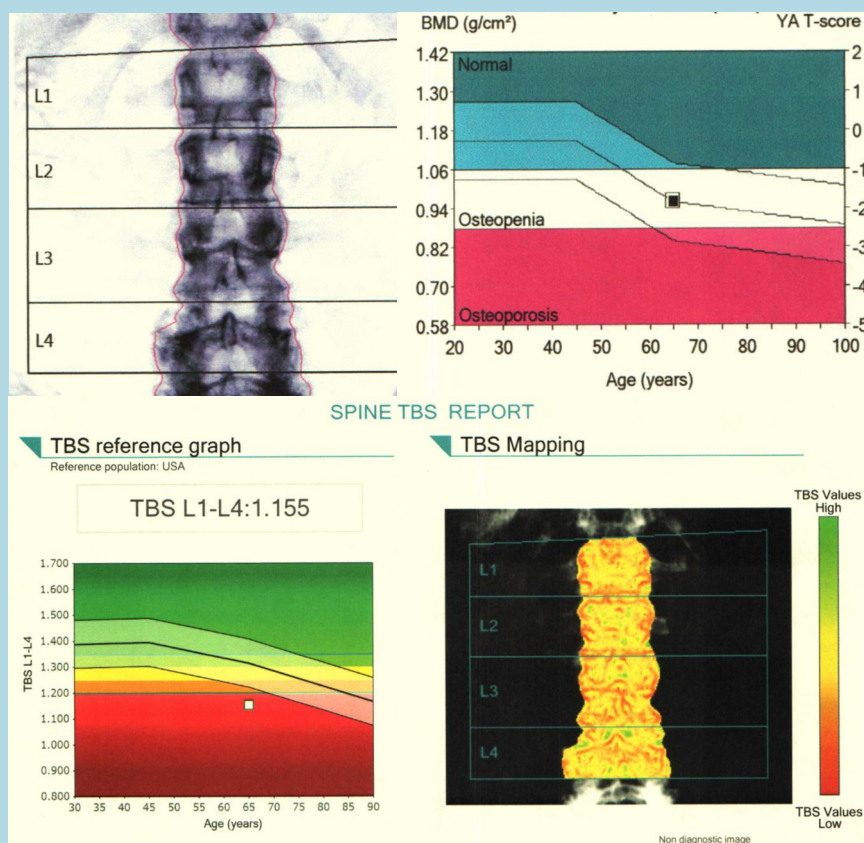
Osteopenic BMD

Spine T-Score (L1-L4): -1.8

Left Femoral Neck T-score: -1.7

Low TBS value

Spine TBS (L1-L4): 1.155



FRAX® 10-year & FRAX Adjusted for TBS Assessment

Country: **US (Caucasian)** Name/ID:

Questionnaire:

1. Age (between 40 and 90 years) or Date of Birth
Age: Date of Birth: Y: M: D:

2. Sex ☐ Male ☒ Female

3. Weight (kg)

4. Height (cm)

5. Previous Fracture ☒ No ☐ Yes

6. Parent Fractured Hip ☐ No ☒ Yes

7. Current Smoking ☒ No ☐ Yes

8. Glucocorticoids ☒ No ☐ Yes

9. Rheumatoid arthritis ☒ No ☐ Yes

10. Secondary osteoporosis ☒ No ☐ Yes

11. Alcohol 3 or more units/day ☒ No ☐ Yes

12. Femoral neck BMD (g/cm²) T-score: -1.7

BMI: 23.0
The ten year probability of fracture (%)

with BMD

Major osteoporotic	18
Hip Fracture	1.2

If you have a TBS value, click here:

The 10 year probability of fracture (%)
Adjusted for TBS

Major Osteoporotic Fracture :	21
Hip Fracture :	1.7

Conclusion & Patient Management Decision

In this individual, the estimated 10-year probability of major osteoporosis related fracture is 18%.

Based on this, she does not meet current NOF guidelines for therapy.

However, her TBS is 1.155.

The 10-year probability of major osteoporotic related fracture adjusted for TBS is 21%. Based upon this, she does meet treatment guidelines.

To learn more about TBS iNsight, please review our white papers:

- *Advanced DXA Using TBS iNsight™*
- *TBS iNsight™ : A Useful Tool to Potentially Reconsider Patient Fracture Risk.*
- *FRAX Adjusted for TBS.*

Medimaps Group Headquarters:
18 chemin des Aulx,
CH-1228 Plan-les-Ouates
(Geneva) - Switzerland
Tel. +41 22 884 86 44


Medimaps Group USA LLC
913N Market Street, Suite 200
Wilmington, DE 19801
Tel. +1 302 416 3063

contact@medimapsgroup.com
www.medimapsgroup.com

TBS iNsight is a trademark of Medimaps Group.
All other trademarks, registered trademarks and product names are the property of their respective owners.

This information is intended for educational purposes, as well as medical professionals in the U.S. and other markets and is not intended as a product solicitation or promotion where such activities are prohibited.

For information on what products are available for sale and in which country, please contact us at contact@medimapsgroup.com


medimaps
we understand bone health